

PennHIP Report

Referring Veterinarian: Dr Mandy Hall	Clinic Name: Stone Ridge Veterinary Medical Center of Conroe
Email: info@conroevets.com	Clinic Address: 2555 S. Loop 336 West Conroe, TX 77304
	Phone: (936) 521-1789
	Fax: (936) 521-1634

Patient Information

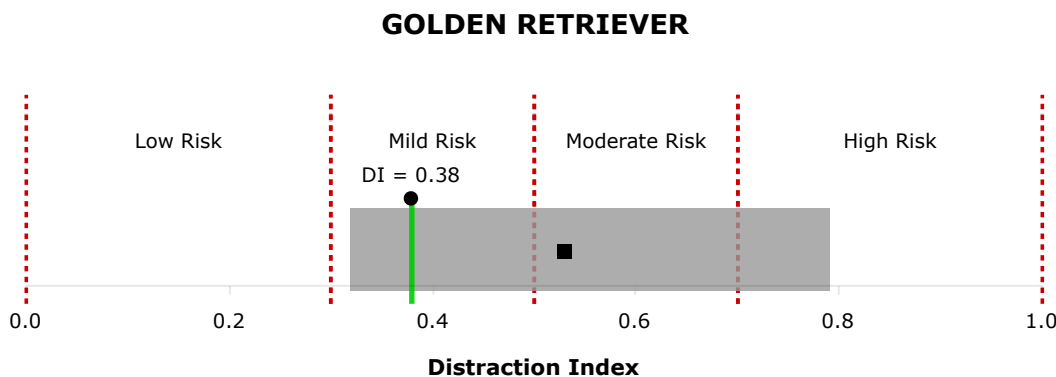
Client: Lund, Sheena	Tattoo Num:
Patient Name: 7-L's Capt. Woodrow F Call	Patient ID: 161934
Reg. Name: 7-L's Capt. Woodrow F Call	Registration Num: SS19615204
PennHIP Num: 163901	Microchip Num: 956000012584056
Species: Canine	Breed: GOLDEN RETRIEVER
Date of Birth: 24 Jun 2020	Age: 16 months
Sex: Male	Weight: 53.1 lbs/24.1 kgs
Date of Study: 22 Oct 2021	Date Submitted: 22 Oct 2021
Date of Report: 28 Oct 2021	

Findings

Distraction Index (DI): Right DI = 0.38, Left DI = 0.32.
 Osteoarthritis (OA): **No radiographic evidence of OA for either hip.**
 Cavitation/Other Findings: No cavitation present.

Interpretation

Distraction Index (DI): The laxity ranking is based on the hip with the greater laxity (larger DI). In this case the DI used is 0.38.
 OA Risk Category: The DI is between 0.31 and 0.49. This patient is at mild risk for hip OA.
 Distraction Index Chart:



BREED STATISTICS: This interpretation is based on a cross-section of 22965 canine patients of the GOLDEN RETRIEVER breed in the AIS PennHIP database. The gray strip represents the central 90% range of DIs (0.32 - 0.79) for the breed. The breed average DI is 0.53 (solid square). The patient DI is the solid circle (0.38).

SUMMARY: The degree of laxity (DI = 0.38) falls within the central 90% range of DIs for the breed. This amount of hip laxity places the hip at a mild risk to develop hip OA. **No radiographic evidence of OA for either hip.**